PLEURAL EFFUSION

Rachel Korman

Pleural effusions may occur in cats due to the following mechanisms:

- Increased capillary hydrostatic pressure e.g. congestive heart failure
- Altered lymphatic drainage e.g. neoplasia within the chest cavity
- Altered capillary integrity e.g. feline infectious peritonitis (FIP), inflammation or
- Decreased colloidal oncotic pressure e.g. hypoalbuminemia.

Fluid can be characterized based on cell numbers and types of cells, the protein content of the fluid, triglyceride and cholesterol content. Traditional fluid types include transudates, modified transudates and exudates. There is often cross-over between categories.

	Transudate	Modified transudate	Exudate	Chylous
Protein g/l	<25	<35	>30-35	20-60
Total nucleated cell count /L	<1000	<5000	>5000	0.4-10
Cell type	Mononuclear	Non-degenerate	Mononuclear cells, neutrophils	Small lymphocytes, non-degenerate neutrophils, macrophages
Associated diseases	Hypoalbuminemia Congestive heart failure Volume overload	Congestive heart failure, low protein, lymphatic obstruction, neoplasia, diaphragmatic hernia	Septic e.g. pyothorax Non-septic e.g. FIP, neoplasia, chronic diaphragmatic hernia, lung lobe torsion, pancreatitis	Idiopathic, congenital, trauma, neoplasia, cardiomyopathy, cranial vena cava thrombus

Please note disease lists are not exhaustive

A simple observation of pleural fluid is:

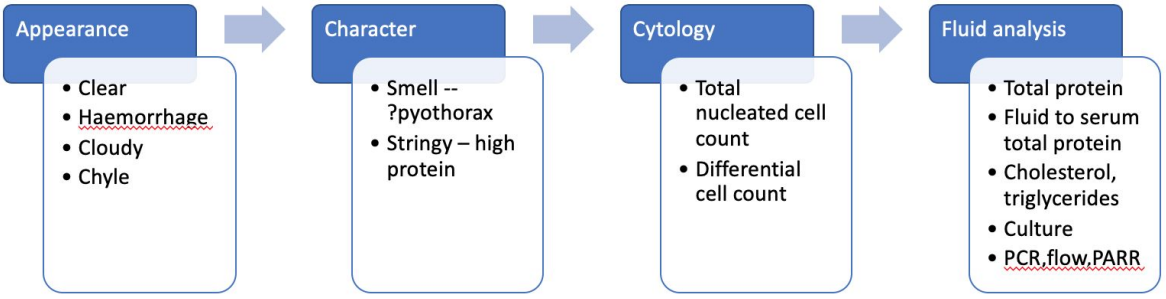

In a study of 380 cats with pleural effusion, 30% failed to survive to discharge. Most cats had effusion due to congestive heart failure (40%) and 26% had effusion due to neoplasia. Cats with a diagnosis of FIP or trauma tended to be younger than cats with congestive heart failure or neoplasia. Cats with lymphoma were younger than cats with carcinoma. Cats with pleural effusion due to congestive heart failure also had lower temperatures. Similar results were found in another study of 306 cats.

Minimising patient stress at all times is key. All staff members (including reception staff) should be trained to question owners and recognise respiratory distress in cats. If identified, cats should be provided with oxygen immediately. The use of oxygen cages appears best tolerated. Cats can be sedated immediately with butorphanol (0.2-0.3 mg/kg SQ or IM) or alfaxalone (2-5 mg/kg SQ or IM).

Further observation of respiratory effort, physical examination, intravenous catheter placement and diagnostic imaging are performed in a sequential manner giving the cat plenty of "down time" between interventions to avoid deterioration in respiratory effort. If severe respiratory effort is present, thoracocentesis can be performed prior to any other diagnostic evaluations. Cardiovascular disease was the most common cause of pleural effusion in cats in two recent studies, so it seems reasonable to administer a conservative dose of frusemide (e.g. 2 mg/kg IV or SQ) prior to further investigations.

Radiographic changes associated with pleural effusion include:

- Increased soft tissue opacity silhouetting the heart
- Retraction/scalloping of lung lobes from thoracic wall (leafing of lung lobes)
- Pleural fissure lines.

Ultrasound is more sensitive for identification of small volume of effusion and also allows for identification of windows for drainage and evaluation of thoracic masses.

Thoracocentesis in cats with pleural effusion is a life-saving procedure. Ensure all equipment is ready prior to drainage.

- Butterfly needle 22G or 22Gx 1.5-inch needle attached to T port
- 3-way tap
- Closed system (empty IV drip bag and giving set connected to 3-way tap)
- 10 ml syringe for collecting samples first
- 20 ml syringe for ongoing drainage
- Sample tubes e.g. EDTA, sterile tube for culture
- Slides for direct smears
- Skin preparation materials
- Alcohol swabs for ultrasound probe

Once set up, the patient can be moved from the oxygen cage to where the procedure is performed. Flow by oxygen is administered. Further sedation can be administered and could include:

- Repeat dose of butorphanol 0.1 mg/kg IV or
- Midazolam 0.2 mg/kg IV/IM + ketamine 2.5 mg/kg IM/IV or
- Acepromazine 0.01-0.05 mg/kg + hydromorphone 0.1 mg/kg IV.

Most cats tolerate thoracocentesis with light sedation, however it is worth having alfaxalone available and be ready to intubate the patient if required.

Often drainage of only one hemithorax is required as the mediastinum in most cats is incomplete but be prepared to drain both sides. Thoracocentesis landmarks are the ventral third aspect of the 7-9th intercostal spaces (ICS). The heart lies approximately at the level of the 3-5th ICS and the liver caudal to the 9th ICS. Avoid the caudal rib margins where intercostal vessels are located. Drainage is performed with the cat is sternal recumbency. Ultrasound is ideal at identifying an appropriate window for drainage. Sterile gloves and aseptic technique should be maintained. The use of alcohol only allows sufficient contact for the ultrasound probe to obtain a decent image. Ideally one person holds and directs the needle, another operates the three way tap and syringe and a third person performs restraint and monitoring of the patient.

The needle is introduced into the thoracic cavity and directed ventrolaterally against the body wall to avoid the lungs. If the tap is negative, the needle is redirected to a different site. If scraping of viscera or bloody froth is obtained the needle should be removed.

Do not empty the drainage syringe completely – leaving approximately 1 ml of fluid in the syringe is useful if fibrin tags block the needle. The fluid can then be injected back into the chest and the needle redirected to facilitate continued drainage.

Potential complications would include lung or viscera laceration. If a patient's respiratory rate or effort remains unchanged or deteriorates further following the procedure it is important to performed thoracic radiographs or repeat ultrasound to look for evidence of pneumothorax or fluid recurrence.

Samples should be submitted for fluid analysis including biochemical analysis for total protein concentration, triglycerides, cholesterol and glucose. Smears and EDTA samples are submitted for cytology to identify predominant cell populations, evaluation for neoplastic cells and bacteria or other organisms. Pleural fluid with a pH <6.9, glucose < 0.6 mmol/L and neutrophils >85% of the total cell count is suggestive of pyothorax. Consideration should be given to perform bacterial culture and infectious disease testing such as coronavirus PCR.

NT-proBNP assays can be performed on both plasma and pleural fluid to help differentiate cardiac from cardiac effusions.

Depending on these test results, further investigations may be required including echocardiography, fine needle aspirate of masses, computed tomography (CT), thoracoscopy or thoracotomy.

Ongoing patient monitoring is important including regular assessment of respiratory rate and effort and to a lesser extent SPO_2 as this could result in further patient anxiety with increased handling.